

DOI 10.2478/pjvs-2014-0082

Short communication

A retrospective study of the occurrence of Chronic Superficial Keratitis in 308 German Shepherd dogs: 1999-2010

Z. Drahovska¹, I. Balicki^{2,3}, A. Trbolova¹, M. Mihalova¹, M. Holickova¹

¹ Small Animal Clinic, University of Veterinary Medicine and Pharmacy in Kosice, Komenskeho 73, 04081 Kosice, Slovakia

² Department and Clinic of Animal Surgery, Faculty of Veterinary Medicine, University of Life Sciences in Lublin, Gleboka 30, 20-612 Lublin, Poland

³ Specialist Veterinary Clinic “Test”, Jana Sawy 3, 20-612 Lublin, Poland

Abstract

Chronic Superficial Keratitis (CSK) is an autoimmune mediated inflammation of the cornea, that is usually bilateral but often with nonsymmetrical manifestation.

The aim of this study was to determine the occurrence and appearance of clinical symptoms of CSK in German Shepherd dogs in Poland and Slovakia.

CSK was diagnosed in 308 German Shepherds for a period of 11 years (from 1999 to 2010). The highest incidence of the CSK ($p < 0.001$) in Slovakia and in Poland was in dogs between the ages of 5-8 years. This study found similarity in gender ratio of affected patients with CSK in two neighboring countries. This disease occurs most often in males, with almost identical frequency in both countries, Slovakia 65.63% and Poland 61.32%, respectively. The incidence of depigmentation and thickening of the external surface of the third eyelid together with CSK was observed in 69.19% of dogs in Poland and in 63.15% of dogs in Slovakia. CSK is often recognized in advanced stage-affected areas with inflammatory process by CSK, obtained frequently from 2 to 3 quadrants.

Key words: dog, Chronic Superficial Keratitis, German Shepherd

Introduction

Chronic Superficial Keratitis (CSK) is an autoimmune bilateral inflammation of the cornea. It has been postulated that the disease can be induced by ultraviolet radiation (Heather et al. 2008). The most often affected breeds are German Shepherds – 82% of cases (Slatter et al. 1977).

Clinical symptoms of CSK are hyperemia of the conjunctiva, corneal vascularisation and edema as well as deposition of pigment in the surface of the cornea. Pathological changes progress from the corneal edge in lateral cantus to the center of the cornea. CSK is often accompanied by depigmentation and thickening of the external surface of the third eyelid. CSK usually affects German Shepherds and their crossbreeds that

Correspondence to: Z. Drahovska, e-mail: z.drahovska@gmail.com, tel.: +42 190 453 12 34

are the age of 4 to 7 years (Stanley 1988, Chavkin et al. 1994).

Diagnostics consist of examination of clinical signs, breed predisposition and differential diagnostic elimination.

Materials and Methods

The study is a retrospective survey of CSK incidence at three veterinary clinics in Poland and Slovakia. For the period of 11 years (from 1999 to 2010) CSK was diagnosed in 308 German Shepherds at the Department and Clinic of Animals Surgery of the University of Life Sciences in Lublin (Poland), the Specialist Veterinary Clinic "Test" in Lublin (Poland) and at the Surgery Department of Small Animal Clinic of the University of Veterinary Medicine and Pharmacy in Kosice (Slovakia). In this period, 5148 patients with ocular problems were examined by authors in Slovakia and 6723 in Poland. Epidemiological analysis was not performed in any country due to the lack of information about the non-pedigree dogs.

All the patients underwent detailed ophthalmic examinations using direct (Keeler, USA Welch Allyn, USA) as well as indirect ophthalmoscopes (PanOptik, Welch Allyn, USA), slit lamp biomicroscopy (Shin Nippon, JP), applanation tonometer (TonoPen, Reichert, USA), Schirmer tear test (Eickemeyer, DE) and fluorescein dyeing (Haag-Streit International, CH).

The age of the patients and the sex ratio of affected animals were considered in the study. Estimation of depigmentation of the third eyelid was noticed as present (+) or absent (-). The quadrants of affected areas with corneal neovascularization and inflammatory process, i.e. neovascularization, fibrous tissue, superficial macular opacities and pigmentation were assessed from photographs.

Statistical analysis about the age having the highest incidence of the CSK in dogs was performed using Chi-square test (StatsDirect Ltd.).

Results and Discussion

The most common occurrence of this disease in dogs in both countries was between 5-6 years of age, and second largest group were dogs between 7-8 years. Notable is the low number of affected animals at the age of 1-2 and over 11 years. A study of Bedford and Longstaffe (1979) revealed that the highest incidence of the CSK was in dogs between the age of 5-8 years. The results of the study performed in Slovakia and Poland were very similar ($p < 0.001$).

In Slovakia, 96 dogs were diagnosed, 65.63% ($n = 63$) of males and 34.37% ($n = 33$) of females. In Poland, 212 dogs were diagnosed with the CSK, 61.32% ($n = 130$) of males and 38.68% ($n = 82$) of females. The CSK disease occurs more often in males with almost identical frequency in both countries. In other studies (Bedford and Longstaffe 1979, Chavkin et al. 1994) the most affected dogs were females. In these studies, 79.8% (Chavkin et al. 1994) to 82% (Bedford and Longstaffe 1979) females had been spayed. It could be the reason why the males in our study are the most affected, because all females were sexually intact, except 5 females in Poland. The apparent gender predilection for CSK among young male and spayed female dogs may reflect some unidentified gender-associated environmental or husbandry factor rather than a protective effect of circulation estrogens (Chavkin et al. 1994). Until now, in veterinary medicine the mechanism of more frequent appearance of CSK and other autoimmune diseases in sterilized females has not been described. The causes of this condition are not explained.

German Shepherd dogs, along with other breeds affected with CSK, often have an elevated risk of developing depigmentation and thickening of the external surface of the third eyelid which, in general, is a rare chronic disease in dogs (Slatter et al. 1977). The swelling and depigmentation of the nictitating membrane margin was reported in the majority of CSK cases (Balicki 2012). The incidence of depigmentation and thickening of the external surface of the third eyelid together with CSK was observed in 69.19% ($n = 146$) of dogs in Poland and in 63.15% ($n = 60$) of dogs in Slovakia. Balicki (2012) and Balicki and Trbolova (2010) pursued depigmentation and repigmentation of the third eyelid before, during and after treatment.

All pathological lesions observed in the cornea are preceded by the neovascularization (Balicki 2012). In Slovakia, the corneas were neovascularized mostly in 3 quadrants in both eyes (32.81%) as opposed to 2 quadrants in Poland (29%). In our study the corneas were highly neovascularized because of late patient's drop- in and the disease was in severe condition (Fig. 1).

Dubielzig et al. (2010) described CSK symptoms as superficial stromal fibrovascular proliferation and scarring with subsequent melanosis. Pigment deposition is a sign of chronicity (Renwick 1996). In previous studies corneal melanosis or corneal pigmentation was not monitored very well in contrast with other symptoms of CSK or in contrast with left and right eye. Balicki (2012) and Balicki and Trbolova (2010) observed the presence of pigmentation in dogs with CSK during the treatment with immunosuppressive drugs. The incidence of pigmentation on the surface

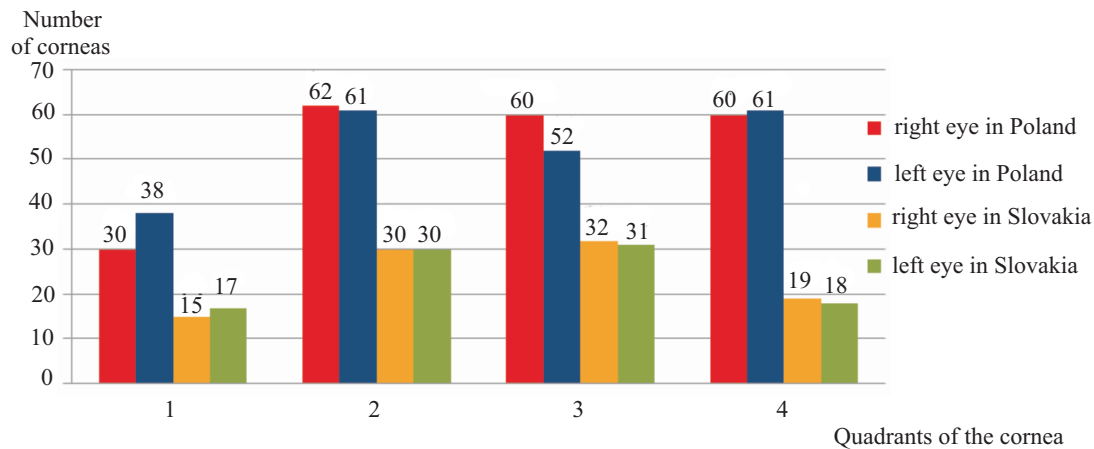


Fig. 1. Corneal areas exhibiting neovascularization in both countries.

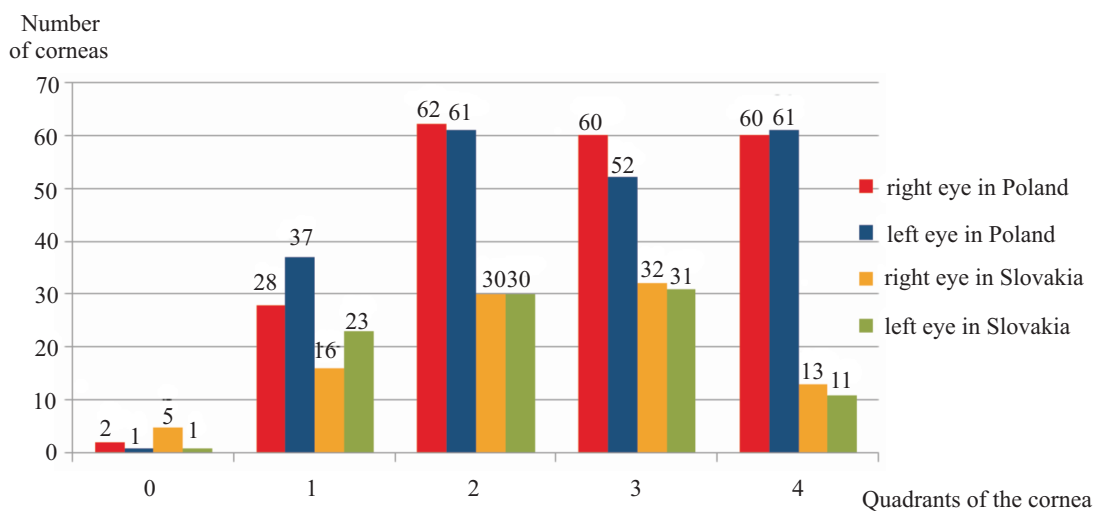


Fig. 2. The number of corneal quadrants affected by CSK in both countries.

of the cornea in our study between both countries was quite similar; the right eye 81.05% in Slovakia, 81.56% in Poland, the left eye 89.47% in Slovakia, 85.78% in Poland. We observed quite high incidence of pigmentation on both eyes in Poland and Slovakia probably because dogs came with severe CSK.

Younger dogs tend to exhibit more vascular and rapidly advancing lesions (Farmer 1984, Renwick 1996). The largest group in Slovakia were dogs between the ages of 5 and 6 years (28.12%) with 3 corneal quadrants affected, in contrast to the largest group in Poland, consisting of the older dogs, between 7 and 8 years of age, with 2 corneal quadrants affected by CSK (Fig. 2).

Clinical findings are manifested mainly bilaterally in 308 patients (99.29%), while in Poland unilateral findings were found in only 3 cases (0.71%).

Acknowledgement

This work was supported by VEGA grant: 1/1192/12

References

- Balicki I (2012) Clinical study on the application of tacrolimus and DMSO in the treatment of chronic superficial keratitis in dogs. *Pol J Vet Sci* 15: 667-676.
- Balicki I, Trbolová A (2010) Clinical evaluation of tacrolimus eye drops for chronic superficial keratitis treatment in dogs. *Bull Vet Inst Pulawy* 54: 251-258.
- Bedford PG, Longstaffe JA (1979) Corneal pannus (chronic superficial keratitis) in the German shepherd dog. *J Small Anim Pract* 20: 41-56.
- Chandler HL, Kusewitt DF, Colitz CM (2008) Modulation of matrix metalloproteinases by ultraviolet radiation in the canine cornea. *Vet Ophthalmol* 11: 135-144.

- Chavkin MJ, Roberts SM, Salman MD, Severin GA, Scholten NJ (1994) Risk factors for development of chronic superficial keratitis in dogs. *J Am Vet Med Assoc* 204: 1630-1634.
- Dubielzig RR, Ketring K, McLellan GJ, Albert DM (2010) Diseases of the eyelids and conjunctiva. In: Dubielzig RR (ed) *Veterinary ocular pathology*, 1st ed., Saunders Elsevier, St. Louis, pp 143-199.
- Farmer AM (1984) Corneal pannus in the dog. *Veterinary Annual* 24: 315-324.
- Renwick P (1996) Diagnosis and treatment of corneal disorders in dogs. *In Practice* 18: 315-328.
- Slatter DH, Lavach JD, Severin GA, Young S (1977) Ueberreiter's syndrome (chronic superficial keratitis) in dogs in the Rocky Mountain area – a study of 463 cases. *J Small Anim Pract* 18: 757-772.
- Stanley RG (1988) Superficial stromal keratitis in the dog. *Aust Vet J* 65: 321-323.