

DOI 10.2478/pjvs-2014-0079

*Short communication*

# The use of magnetic resonance imaging in diagnosing equine deep digital flexor tendinopathies – own experience

**M. Jaskólska, Z. Adamiak, P. Holak, Y. Zhalniarovich, P. Przyborowska, Z. Peczyński**

Department of Surgery and Radiology, Faculty of Veterinary Medicine,  
University of Warmia and Mazury, Oczapowskiego 14, 10-957 Olsztyn, Poland

## Abstract

Deep digital flexor tendinopathy is a common problem in horses of different athletic disciplines. Nowadays, the use of magnetic resonance imaging is considered to be a noninvasive and superior choice for recognizing bone and soft tissue pathologies especially related to difficult to access structures within the hoof capsule.

**Key words:** magnetic resonance imaging, deep digital flexor tendon, navicular syndrome, horse

## Introduction

Deep digital flexor tendinopathy may appear as an acute onset traumatic injury or as a result of repetitive stress. Predisposing factors may be connected with hoof conformation, distal phalanx angle, angle of the DDFT lying caudally to the navicular bone, athletic discipline, neurectomy and navicular bone disorders (Schramme 2011). There are four main types of the DDFT injuries: core lesions, dorsal abrasions, sagittal plane and oblique splits, insertional lesions.

## Materials and Methods

The study was performed on horses which were subjected to magnetic resonance imaging due to the positive response to the palmar digital nerve block,

but in which radiographic examination revealed no abnormalities. Four patients were dressage horses and two were showjumpers. All horses had forelimb lameness of few months duration (4-7 months). Local anesthetic techniques included perineural analgesia of the palmar digital nerves. Two horses responded positively to the block performed proximal to the ungual cartilages, and five horses showed positive reaction to the block performed at the base of the proximal sesamoid bones. The anesthetic solution was 2% lidocaine (Lignocainum hydrochloricum 2% inj, Polfa Warszawa). The injected volume was 1,5-2 ml per site. Lameness was evaluated 10 minutes after perineural analgesia. Radiographic examination in lateromedial and dorsoproximal-palmarodistal oblique views revealed no significant abnormalities. The MRI examination was performed under general anesthesia with the use of a low-field scanner with a field strength

---

Correspondence to: M. Jaskólska, e-mail: marta.jaskoolska@gmail.com

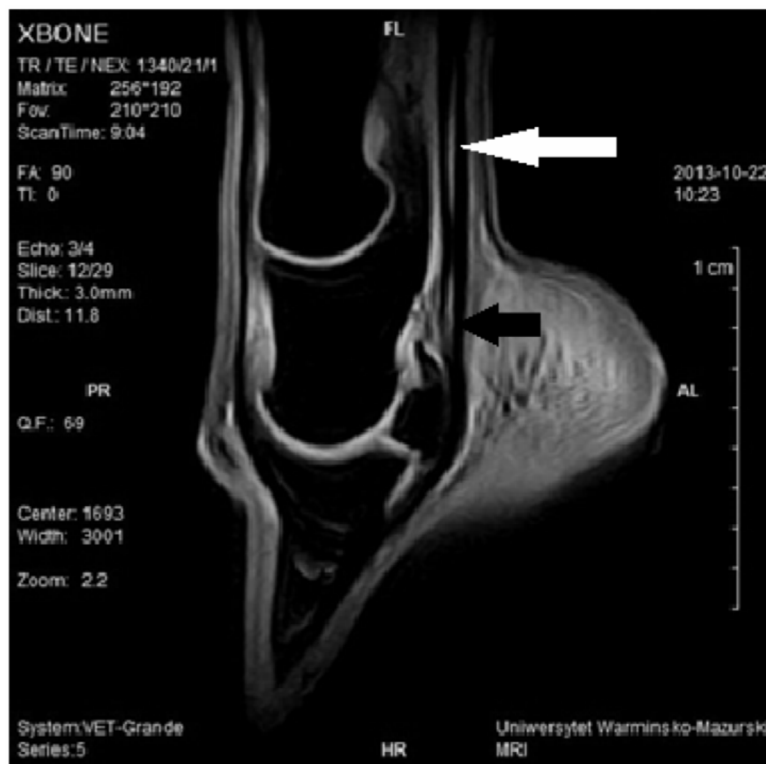

Fig. 1. A sagittal view of the six years old Holsteiner dressage gelding with the left forelimb lameness of 5 months duration. The horse was positive to the abaxial sesamoid nerve block. There is a core lesion in the DDFT at the level of the distal end of the proximal phalanx extending to the level of the middle phalanx (white arrow). Concurrent lesion is present caudally to the proximal recess of the navicular bursa, with irregular dorsal surface of the DDFT and increased signal intensity between the DDFT and the navicular bursa (black arrow).

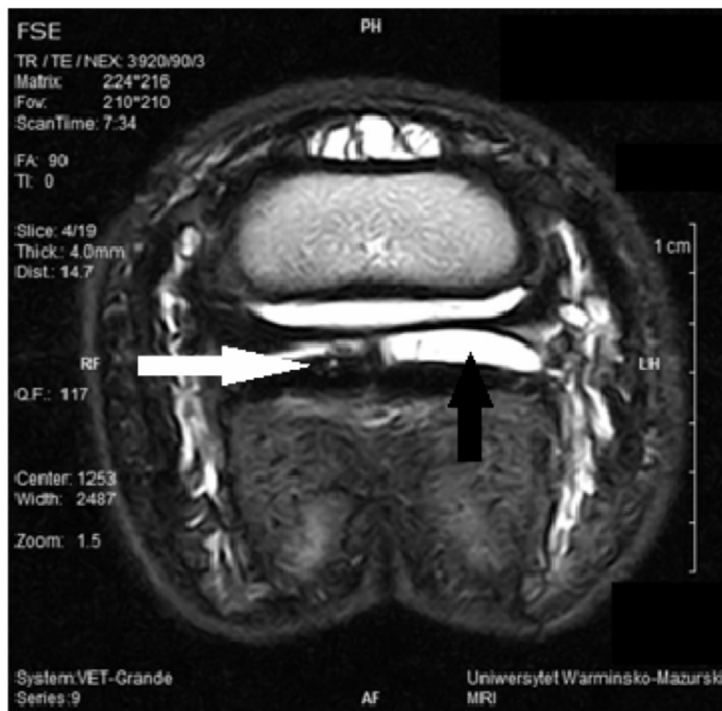


Fig. 2. A transverse T2 FSE view of the left front limb of the eight years old Hanoverian mare. The lameness was five months duration and the mare was positive to the palmar digital nerve block. There is increased signal intensity in the dorsal part of the lateral DDFT lobe, with narrowing of the lateral navicular bursa recess (white arrow) and increased amount of fluid in the medial navicular bursa recess (black arrow).

of 0.25 T (Vet Grande, Esaote, Italy). The distal limb was scanned in sagittal, transverse and dorsal planes, with the use of following sequences: XBone T1, T2 FSE, STIR, PD SE, 3D Sharc. Comparing results received from different sequences may provide reliable diagnosis (Jaskolska et al. 2013).

## Results and Discussion

Deep digital flexor tendon injuries appeared as core lesions (two cases) and dorsal abrasions (four cases). Core lesions (Fig. 1) are usually seen at the level of proximal interphalangeal joint and proximal phalanx (Dyson and Murray 2007). The length of injury may vary. In this study the length of the lesion was 79,59 mm in one case and 55,30 mm in the second case. Core lesions are characterized as collagen necrosis, fibroplasia and fibrocartilagenous metaplasia (Schramme 2011). Dorsal abrasions are usually seen concurrently with navicular bursa pathologies as was in one case in that study (Fig. 2). They are characterized as fibrillations or erosions. The connection between the lesion and navicular bursa could be suspec-

ted, but to prove it the contrast into navicular bursa should be injected (Maher et al. 2011), which was not performed in that study. The prognosis for the DDFT injuries is guarded and dependent on the injury type and structures concurrently involved. This fact implies the necessity of usage MRI examination in the DDFT problems in horses.

## References

- Dyson S, Murray R (2007) Magnetic resonance imaging evaluation of 264 horses with foot pain: the podotrochlear apparatus, deep digital flexor tendon and collateral ligaments of the distal interphalangeal joint. *Equine Vet J* 39: 340-343.
- Jaskolska M, Adamiak Z, Zhalniarovich Y, Holak P, Przyborowska P (2013) Magnetic resonance protocols in equine lameness examination, used sequences, and interpretation. *Pol J Vet Sci* 16: 803-811.
- Maher CM, Werpy NM, Goodrich LR, McIlwraith CW (2011) Positive contrast magnetic resonance bursography for assessment of the navicular bursa and surrounding soft tissues. *Vet Radiol Ultrasound* 52: 385-393.
- Schramme MC (2011) Deep digital flexor tendonopathy in the foot. *Equine Vet Educ* 23: 403-415.